

# Miniaturized Electromagnetic Device Abutment Improves Stability of the Dental Implants

Shlomo Barak, DMD,\* Shlomo Matalon, DMD,<sup>†</sup> Oleg Dolkart, PhD,<sup>‡</sup> Barbara Zavan, PhD,<sup>§</sup> Carmen Mortellaro, MD, DDS,<sup>||</sup> and Adriano Piattelli, MD, DDS<sup>¶</sup>

**Background:** The overall success and predictability of dental implant treatment hinge on the primary stability, direct bone-to-implant contact formation, and quantity and/or quality of residual bone. Pulsed electromagnetic field has been reported to increase bone regeneration in various clinical situations. Therefore, it was hypothesized that devices which could locally generate a Pulsed electromagnetic field would stimulate bone healing and increase bone density surrounding implants.

**Objective:** To retrospectively assess the effects of the miniaturized electromagnetic device (MED) on the implants stability for the first time in human subjects, in a prospective case controlled series.

**Methods:** Twelve consecutive patients (28 implants) were included in the study.

Twelve MED healing caps and 16 regular control healing caps were inserted. Resonance frequency analysis (RFA) was performed at implant placement and abutment connection and an implant stability quotient value was given for each implant.

**Results:** Twenty-eight dental implants were included in the current study. Maxillary implants stability was significantly higher with MED healing caps compared with controls at 15 days postimplantation (66.2 vs 62.1,  $P = .0008$ ). Resonance frequency analysis test performed at 30 days postimplantation demonstrated significantly increased stability in MED as compared with the control  $73.5 \pm 3.2$  vs  $66.7 \pm 4.8$  in mandibular implants and  $74 \pm 1.7$  vs  $65 \pm 2.3$  in maxillary implants. At the 50 days postimplantation, RFA tests revealed markedly higher stability of the maxillary implants with MED active healing caps compared with nonactive  $75.4 \pm 5.1$  vs  $68.5 \pm 8.5$ , respectively.

**Conclusions:** We conclude that MED-abutment implants demonstrated a superior stability during the early phase of healing as compared with standard implants.

**Key Words:** Bone regeneration, dental implants stability, electromagnetic device, magnetic field

(*J Craniofac Surg* 2018;00: 00–00)

Dental implant longevity is largely determined by osseointegration. Factors pertinent to the success and reliability of dental implants include primary stability, bone to implant contact formation, quality and quantity of residual bone. Ideal implant materials should display advantageous biocompatibility and mechanical characteristics.<sup>1,2</sup> Currently, implants constructed of titanium are ubiquitous in dentistry secondary to their favorable characteristics including properties that allow the formation of an osseous integration of the implant. However, implants currently on the market customarily require a 2 to 6-month period without loading of the device to allow adequate time for osseointegration.

Current literature demonstrates that attenuating the unloading time postimplantation increases failure rate by 2 or 3 times, especially in unsplinted dental devices.<sup>3–5</sup> Osseointegration or union of alveolar bone and dental implant is one of the primary goals of dental implantation. Thus, multiple therapies targeting enhancing osseointegration or reducing time to achieve osseointegration have been proposed.

Pulsed electromagnetic field (PEMF) is one modality commonly used to stimulate bone generation throughout various clinical settings including orthopedic surgery. Pulsed electromagnetic field has been shown to primarily effect vascular generation, formation, and neovascularization.<sup>5,6</sup> In dentistry PEMF stimulation may be a useful tool to encourage bone formation, ingrowth of bone on dental implants, and increased bone stock. This may help decrease time to osseointegration and allow patients to return to normal loaded eating activities sooner (Table 1).

A recently published study by Barak et al<sup>7</sup> reported that in rabbits PEMF devices stimulated early osseointegration and ingrowth of bone onto dental implants by more than 3 times. It was therefore hypothesized that dental implant devices locally generating PEMF stimulation would significantly stimulate bone growth and increase osseointegration around the implant PEMF devices themselves.

This study was designed to retrospectively assess the effects of the miniaturized electromagnetic device (MED) on the implants stability for the first time in human subjects, in a case controlled series (Fig. 1).

## METHODS

### Subjects

The local institutional review board approved this retrospective cohort study. Medical records and radiographic images of patients who presented to our center between 2014 and 2016 were reviewed. Twelve partially edentulous patients (7 females) in the mandible or the maxilla with a buccolingual ridge width of at least 6mm and with opposing dentition of natural teeth or tooth-

From the \*Private Practice; <sup>†</sup>Department of Oral Rehabilitation, The Maurice and Gabriela Goldschleger School of Dental Medicine, Tel Aviv University, Ramat Aviv; <sup>‡</sup>Division of Orthopaedic Surgery, Tel Aviv Sourasky Medical Center, Tel Aviv University Sackler Faculty of Medicine, Tel Aviv, Israel; <sup>§</sup>Department of Biomedical Sciences, University of Padua, Padua; <sup>||</sup>Department of Medical Science, University of Eastern Piedmont, Novara; and <sup>¶</sup>Department of Medical, Oral and Biotechnological Sciences, University of Chieti-Pescara, Chieti, Italy.

Received April 29, 2018.

Accepted for publication May 23, 2018.

Address correspondence and reprint requests to Oleg Dolkart, PhD,

Orthopedic Surgery Division, Tel-Aviv Medical Center, 6 Weizman Street, Tel Aviv 6423906, Israel; E-mail: dolkarto@gmail.com

Barak S is a founder of Magdent Ltd, and Dolkart O is a paid consultant of Magdent Ltd. The remaining authors report no conflicts of interest.

Copyright © 2018 by Mutaz B. Habal, MD

ISSN: 1049-2275

DOI: 10.1097/SCS.00000000000004763

**TABLE 1.** Resonance Frequency Analysis Results

	Mandible			Maxilla		
	Control	MED	pV	Control	MED	pV
Baseline	56.2 ± 4.8	59.33 ± 4	0.24	60.9 ± 1.6	61.2 ± 1.2	0.7
Day 15	61.3 ± 4.8	66.3 ± 4	0.07	62.1 ± 2.1	66.2 ± 0.7	0.0008*
Day 30	66.7 ± 4.8	73.5 ± 3.2	0.016	65 ± 2.3	74 ± 1.7	<0.05*
Day 50				68.5 ± 8.5	75.4 ± 5.1	<0.05*

Results are reported as mean ± SD.  
 MED, miniaturized electromagnetic device.  
 \*P < .05 MED versus Control group, T test.

implant-supported fixed reconstructions were assessed. Twelve Magdent healing caps (MED) and 16 regular control healing caps were inserted.

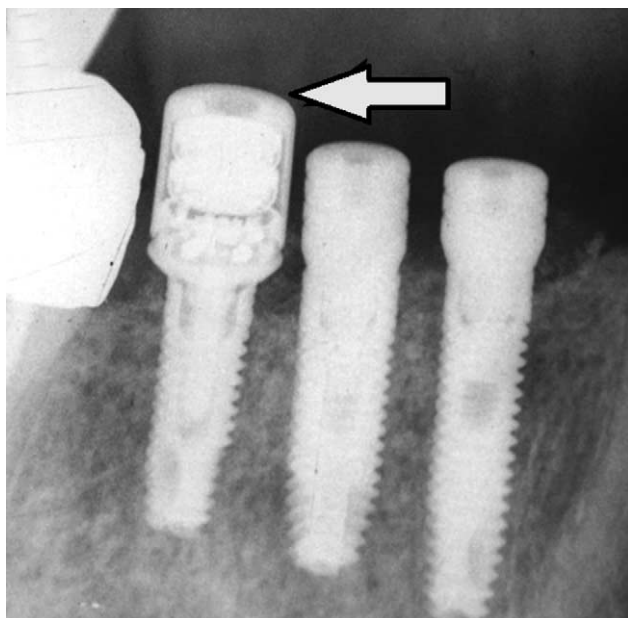
The mean age at implant surgery was 49 years (range 34–69). Prior to inclusion in the study, all patients were examined according to a standardized protocol with clinical and radiographic examination.

The following inclusion criteria were used:

- controlled oral hygiene
- absence of any lesions in the oral cavity
- sufficient residual bone volume to receive implants of at least 3.7 mm in diameter and 11.5 mm in length.

**Surgical Procedures**

Surgical procedures were performed in outpatient clinics under local anesthesia. Implants (Alpha-Bio Tec Ltd, Petah Tikva, Israel) were placed according to standard protocols. To achieve the highest standardization of the initial bone-level situation, each implant was placed at the bone level. Antibiotics will be prescribed according to the standard practice at the clinic. After implantation, a MED was



**FIGURE 1.** Arrow is showing MED healing cup. MED, miniaturized electromagnetic device.

applied to the implant. Electromagnetic stimulation was administered continuously for 24 hours a day using a MED healing cap (Magdent Ltd, Tel Aviv, Israel). Identical devices and the same follow-up protocol were used for both control and PEMF cases.

**Postoperative Procedures**

Patients were educated in postoperative dental hygiene and care procedures. They followed standard instructions for implant patients, including instructions not to brush in the treated area and to rinse twice per day for 1 minute with 0.1% to 0.2% chlorhexidine digluconate. Sutures were removed 2 weeks after surgery. The extent of healing and any local inflammation of the soft tissue around the study implant were assessed.

**Resonance Frequency Analysis**

During healing, resonance frequency analysis (RFA) were performed, starting with an assessment immediately following implant installation (Week 0) and then at following weeks: mandible—at 2w and 4w, maxilla: 2, 4, and 8w, postoperatively. The wireless Osstell device was used for this study (Osstell Mentor, Integration diagnostics AB, Sävedalen, Sweden). Resonance frequency analysis measurements were carried out in 2 perpendicular directions (mesio-distal [M-D] and oro-facial [O-F]), twice in each direction. Resonance frequency analysis was performed at implant placement and abutment connection and an implant stability quotient value was given for each implant.

**Statistical Analyses**

Descriptive statistics were calculated with measures of central tendency (mean and median), measure of dispersion (standard deviation), and 95% confidence interval. Data from 28 implants were analyzed using SPSS21.0 software (SPSS Inc, Chicago, IL), applying the Wilcoxon test according to the nature of the data. The significance level was established at P < 0.05.

**RESULTS**

Twenty-eight dental implants were included in the current study. Following implantation, the patients reported no or only minor discomfort at the surgical sites.

No statistical significant difference in stability was found between the mandibular implants at the first 15 days. Maxillary implants stability was significantly higher with MED healing cups compared with controls at the day 15 postimplantation (66.2 vs 62.1, P = .0008). Resonance frequency analysis test performed at day 30 postimplantation demonstrated a significantly higher stability results in MED as compared with the control 73.5 ± 3.2 versus 66.7 ± 4.8 at mandible and 74 ± 1.7 versus 65 ± 2.3 at maxilla. At the day 50 postimplantation, RFA test revealed markedly higher stability of the maxillary implants with MED active healing caps compared with nonactive 75.4 ± 5.1 versus 68.5 ± 8.5, respectively.

**DISCUSSION**

The principal outcomes of this study demonstrated improved MED implant at 30 and 50 days postimplantation. Moreover, maxillary implants stability was significantly higher in MED healing cups than in control cups at the early 15 day postimplantation time point.

Establishing implant stability and long-term maintenance of implant stability are imperative for clinical success of dental implants. Contact area between bone stock and implant, implantation technique, and bone quality are all factors influencing osseointegration and successful implantation outcomes. Initial mechanical implant stability is largely mediated by contact area, and thus friction or macro-retentions between the implant and its insertion

site. Later biological stability is a product of the boney ingrowth and tissue integration which occurs after allowing ample time for healing.<sup>8</sup>

Dental implant failures are often classified as early failures and late failures. Early failures occur at abutment connection surgery, whereas late failures occur secondary to occlusal loading after healing. This classification and knowledge of the time course for healing suggests that early and late failures are associated with different mechanisms. Early failure is the result of inadequate bone to implant contact area. Bone healing and ingrowth in these cases may be impaired.<sup>9</sup> Other factors that have the potential to influence bone healing include poor oral hygiene, risky behaviors, and systemic diseases. Additionally, radiotherapy, surgical conditions, and medication usage may all play a role in the ultimate clinical outcome of dental implants.

To achieve successful dental implant therapy achieving osseointegration in the shortest time possible is imperative.<sup>10</sup> Targeted treatments have been proposed to improve and accelerate osseointegration at the dental implant–bone interface. Low-level laser therapy is one technique studied in animals which was shown to increase bone–implant contact on a microscopic level.<sup>11–13</sup> Furthermore, low-level laser therapy was shown to enhance the association between native bone and prosthetic implant<sup>14</sup> increases the percentage of calcium and phosphorus in local bone stock<sup>12</sup> and increases production of OPG, RANKL, and RANK in the local environment.<sup>15</sup> These results are supported by recent literature of dental implants in a rabbit model.<sup>7</sup> However, there are no clinical studies reporting statistically significant macroscopic results.<sup>16,17</sup>

Research has shown that electromagnetic stimulation promotes osteogenic activity and multiple studies have demonstrated the effectiveness of externally applied electromagnetic stimulation in various clinical settings<sup>6</sup> including dentistry.<sup>18</sup> These studies have demonstrated reduced time to osseointegration surrounding dental implants when external source of electromagnetic stimulation is applied. Recent work using a rabbit model has shown that PEMF devices stimulate early bone formation around dental implants and produce higher peri-implant BIC as well as increased bone mass with as little as 2 weeks of therapy. This suggests accelerated osseointegration with PEMF stimulation in the setting of dental implants.<sup>7</sup>

This study has several limitations including the small sample size. Furthermore, Osstel was employed as the sole instrument used for functional assessment, using other instruments could have strengthened the results.

This is the first clinical study examining the effects of dental implant devices with internal PEMF stimulators. This device produces an electromagnetic field around the implant similar to that of external devices. The advantage of this device is that the effective electromagnetic field is directed exclusively around the dental implant and there is no need to use an external PEMF source. This allows for continuous activation of the PEMF device for 24 hours a day with the goal of achieving improved implant stability in the early postimplantation stage. Moreover, patient compliance with external hardware does not interfere with the treatment. Further randomized controlled trials in larger cohorts assessing

the clinical outcomes after implantation of the MED device are warranted.

## REFERENCES

- Javed F, Ahmed HB, Crespi R, et al. Role of primary stability for successful osseointegration of dental implants: factors of influence and evaluation. *Interv Med Appl Sci* 2013;5:162–167
- Sakka S, Baroudi K, Nassani MZ. Factors associated with early and late failure of dental implants. *J Investig Clin Dent* 2012;3:258–261
- Esposito M, Grusovin MG, Achille H, et al. Interventions for replacing missing teeth: different times for loading dental implants. *Cochrane Database Syst Rev* 2009;CD003878
- Gallucci GO, Morton D, Weber HP. Loading protocols for dental implants in edentulous patients. *Int J Oral Maxillofac Implants* 2009;24(suppl):132–146
- Smith TL, Wong-Gibbons D, Maultsby J. Microcirculatory effects of pulsed electromagnetic fields. *J Orthop Res* 2004;22:80–84
- Fu YC, Lin CC, Chang JK, et al. A novel single pulsed electromagnetic field stimulates osteogenesis of bone marrow mesenchymal stem cells and bone repair. *PLoS One* 2014;9:e91581
- Barak S, Neuman M, Iezzi G, et al. A new device for improving dental implants anchorage: a histological and micro-computed tomography study in the rabbit. *Clin Oral Implants Res* 2016;27:935–942
- Abrahamsson I, Berglundh T, Linder E, et al. Early bone formation adjacent to rough and turned endosseous implant surfaces. An experimental study in the dog. *Clin Oral Implants Res* 2004;15:381–392
- Alsaadi G, Quirynen M, Komarek A, et al. Impact of local and systemic factors on the incidence of oral implant failures, up to abutment connection. *J Clin Periodontol* 2007;34:610–617
- Albrektsson T, Branemark PI, Hansson HA, et al. Osseointegrated titanium implants. Requirements for ensuring a long-lasting, direct bone-to-implant anchorage in man. *Acta Orthop Scand* 1981;52:155–170
- Jakse N, Payer M, Tangl S, et al. Influence of low-level laser treatment on bone regeneration and osseointegration of dental implants following sinus augmentation. An experimental study on sheep. *Clin Oral Implants Res* 2007;18:517–524
- Khadra M, Ronold HJ, Lyngstadaas SP, et al. Low-level laser therapy stimulates bone-implant interaction: an experimental study in rabbits. *Clin Oral Implants Res* 2004;15:325–332
- Pereira CL, Sallum EA, Nociti FH Jr et al. The effect of low-intensity laser therapy on bone healing around titanium implants: a histometric study in rabbits. *Int J Oral Maxillofac Implants* 2009;24:47–51
- Ren C, McGrath C, Yang Y. The effectiveness of low-level diode laser therapy on orthodontic pain management: a systematic review and meta-analysis. *Lasers Med Sci* 2015;30:1881–1893
- Gomes FV, Mayer L, Massotti FP, et al. Low-level laser therapy improves peri-implant bone formation: resonance frequency, electron microscopy, and stereology findings in a rabbit model. *Int J Oral Maxillofac Surg* 2015;44:245–251
- Garcia-Morales JM, Tortamano-Neto P, Todescan FF, et al. Stability of dental implants after irradiation with an 830-nm low-level laser: a double-blind randomized clinical study. *Lasers Med Sci* 2012;27:703–711
- Mandic B, Lazic Z, Markovic A, et al. Influence of postoperative low-level laser therapy on the osseointegration of self-tapping implants in the posterior maxilla: a 6-week split-mouth clinical study. *Vojnosanit Pregl* 2015;72:233–240
- Matsumoto H, Ochi M, Abiko Y, et al. Pulsed electromagnetic fields promote bone formation around dental implants inserted into the femur of rabbits. *Clin Oral Implants Res* 2000;11:354–360